THE ANATOLIAN JOURNAL OF CARDIOLOGY

Official journal of the TURKISH SOCIETY OF CARDIOLOGY

A Fatal Symphony of Thrombus and Turbulence: A Case of Coronary Artery Fistula with Giant Pseudoaneurysm

An 80-year-old woman presented with recurrent fatigue and amaurosis fugax. Transthoracic echocardiography revealed a large solid mass in the right atrioventricular groove with an anechoic area (Figure 1A). Myocardial contrast echocardiography showed the solid component lacked contrast opacification, suggesting thrombus, while the anechoic area communicated with the coronary artery, showing contrast intensity equal to the left ventricular cavity but with delayed filling (Figure 1B). Computed tomography angiography (CTA) diagnosed a left anterior descending and right coronary branch-to-pulmonary artery fistula with aneurysmal dilation of the fistulous vessel and a large pseudoaneurysm in the right atrioventricular groove, accompanied by mural thrombus, showing signs of impending rupture and compressing adjacent chambers (Figure 1C, 1D, and 1E). Preprocedural digital subtraction angiography clearly revealed the pseudoaneurysm (Figure 1F). After assessment, percutaneous interventional therapy was performed. Guided by optical coherence tomography, 4 drug-eluting covered stents were implanted in series within the right coronary artery, achieving complete coverage of the aneurysm neck and adjacent diseased segments. The procedure was successful. Follow-up CTA on postoperative day 2 demonstrated patency of the right coronary artery stents and closure of the original aneurysm, with no residual flow within the thrombosed cavity (Figure 1G). Three-month follow-up echocardiography showed shrinkage of the aneurysm cavity with no detectable blood flow signal (Figure 1H and 1I). The patient's symptoms resolved, and she remained stable during follow-up. Given the life-threatening rupture risk, advanced age, and high surgical risk in this patient, percutaneous intervention was considered the optimal strategy to prevent rupture.

E-PAGE ORIGINAL IMAGE

Informed Consent: Written informed consent was obtained from the patient for publication of this case report and any accompanying images.

Declaration of Interests: The authors have no conflict of interest to declare.

Funding: Supported by: Open Fund of Wuhan Clinical Medical Research Center for Cardiovascular Imaging (CMRC202317).

Yanqiu Zhang[1]
Mengqi Tang[1,2]
Xiaojing Ma[1]
Yafeng He[1]
Zhengchun Yu[1]

[1]*Department of Ultrasound, Wuhan Asia Heart Hospital Affiliated to Wuhan University of Science and Technology, Wuhan Clinical Medical Research Center of Cardiovascular Imaging, Wuhan, China*
[2]*Wuhan University of Science and Technology School of medicine, Wuhan, China*

Corresponding author:
Zhengchun Yu
✉ 13089833664@163.com

Available Online Date:
November 10, 2026

Cite this article as: Zhang Y, Tang M, Ma X, He Y, Yu Z. A fatal symphony of thrombus and turbulence: a case of coronary artery fistula with giant pseudoaneurysm. *Anatol J Cardiol.* 2026;XX(X):X-X.

DOI: 10.14744/AnatolJCardiol.2026.7102

Copyright@Author(s) - Available online at anatoljcardiol.com.
Content of this journal is licensed under a Creative Commons Attribution-NonCommercial 4.0 International License.

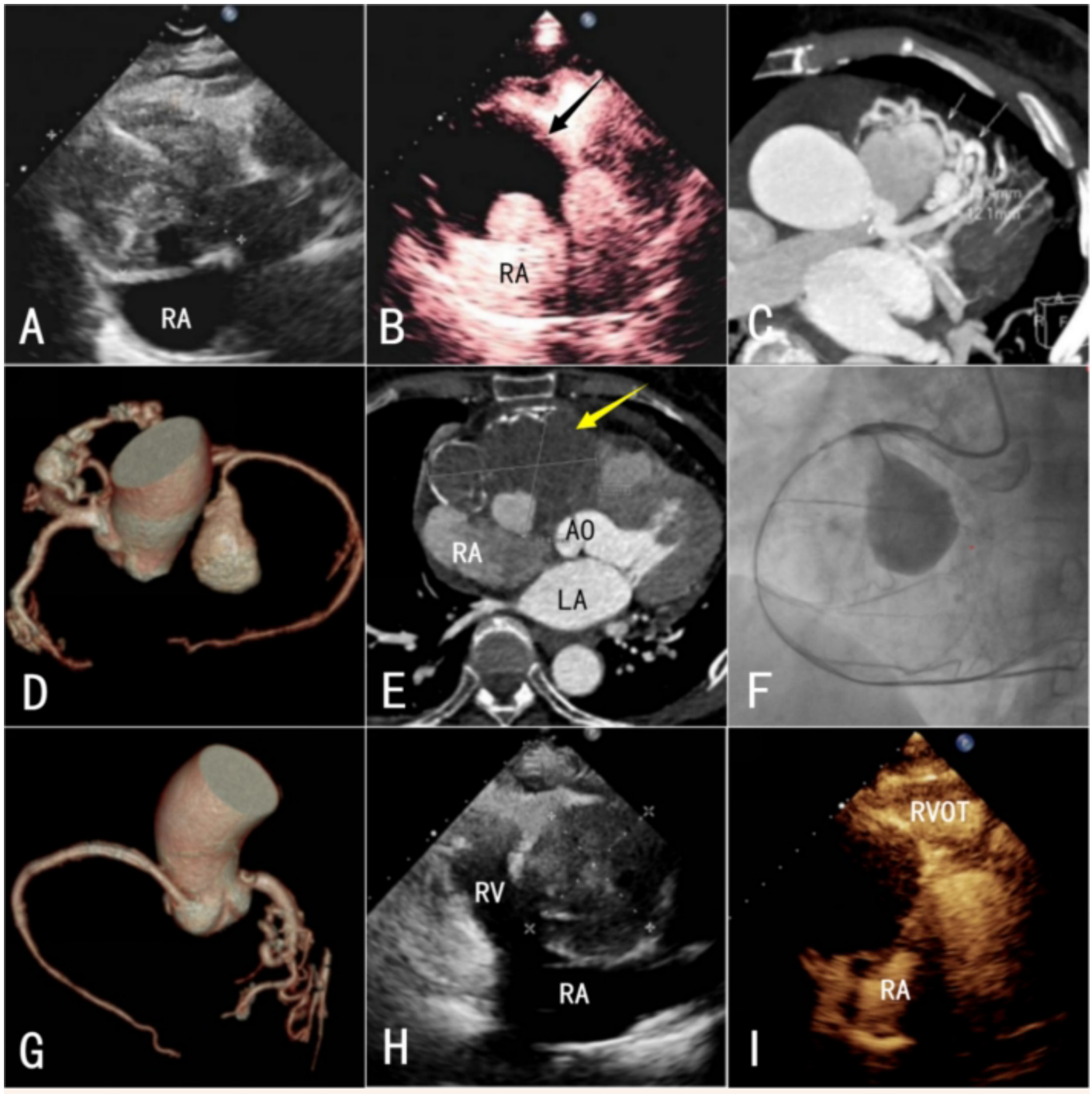

Figure 1. (A) Echocardiography shows a solid mass in the right atrioventricular groove. (B) MCE shows no contrast opacification within the solid component of the mass, while contrast filling is observed within the anechoic area. (C) CT shows a left anterior descending and right coronary branch-to-pulmonary artery fistula. (D) Three-dimensional reconstruction reveals the pseudoaneurysm. (E) CT shows a giant pseudoaneurysm in the right atrioventricular groove. (F) DSA shows the pseudoaneurysm. (G) Postoperative 3-dimensional reconstruction shows no evidence of the pseudoaneurysm. (H) Echocardiography shows reduction in the size of the solid mass compared with previous imaging. (I) LVO shows no contrast opacification within the mass, and the original anechoic area has disappeared. CT, computed tomography; DSA, digital subtraction angiography; LVO, left ventircular opacification; MCE, myocardial contrast echocardiography.